

## **Diagnosis of Different Strains of Infectious Bronchitis of Broilers With Polymerase Chain Reaction (PCR) In Dakahlia Governorate**

**\* Rania I.Mohamed and \*\* Ghada A.A.**

\* Department of Pathology, Animal Health Research Institute, Agriculture Research Center, EGYPT,-  
Mansoura Provincial Lab.

\*\* Department of Poultry Diseases, Animal Health Research Institute, Agriculture Research Center,  
EGYPT, -Mansoura Provincial Lab.

### **Abstract**

Infectious bronchitis virus (IBV) is one of the most important viral diseases of poultry, it causes major economic losses to poultry industry. New IBV geno- and serotypes are continually reported from all over the world and especially from Egypt. This study was conducted to investigate the prevalence of different strains of (IBV) in commercial broiler flocks in Dakahlia governorate. Fifty birds suffering from respiratory disease were collected from five farms. These birds were necropsied and examined for the Presence of pathological changes in trachea, lungs, kidneys, spleen and heart. Five Pooled samples of trachea, lungs, air sacs, heart and spleen and kidneys were tested for the presence of IBV, using the reverse-transcription polymerase chain reaction. Four of them were positive for IBV by RRT-PCR. Positive samples were amplified by RRT-PCR using specific primers for S1 gene. One was genetically characterized as IBV Variant 2 closely related to infectious bronchitis virus isolate Eg/12120s/2012 spike glycoprotein (SP1) gene with identity homology of approximately 99% and Avian infectious bronchitis virus isolate IS/1494/06 spike glycoprotein gene, with identity homology of 96%. The second was genetically characterized as IBV Variant 2 closely related to Infectious bronchitis virus isolate Eg/12120s/2012 spike glycoprotein (SP1) gene with identity homology 95% and Avian infectious bronchitis virus isolate IS/885 S1 spike glycoprotein gene, identity homology 93%. Tissue specimens from positive birds were prepared, stained and examined microscopically for histopathological changes and immunohistochemistry. Grossly, intense tracheitis with presence of mucus or caseous exudates could be seen inside trachea and respiratory airways beside focal pneumonic areas were common. Regarding histopathological lesions, trachea showed intense catarrhal tracheitis accompanied by loss of cilia. Lungs revealed caseous plug inside primary bronchus. Air sacs showed air sacculitis with pneumonia. Spleen had multifocal areas of coagulative necrosis. IBV antigen was detected by avidin biotin immunoperoxidase technique using IB Ab Igg prepared in chicken as primary monoclonal antibody. Dense brown granules were detected in lungs, trachea, kidneys and heart.

These results were consistent with virus detection by RRT-PCR and histopathological changes. Future work should include the isolation and serotyping of IBV in the region, so that a suitable vaccination program, using the common field serotypes as vaccines, can be adopted to protect against IBV caused disease.

Keywords: broilers/immunohistochemistry/infectious bronchitis/PCR/histopathology.

### Introduction

Infectious bronchitis (IB) is an acute, highly contagious and economically important viral disease that occurs in commercial chickens of all ages. It is caused by the infectious bronchitis virus (IBV) (**Cavanagh and Gelb, 2008**), a member of the genus *Gammacoronavirus*, family *Coronaviridae*, with more than 26 serotypes (**King et al., 2012**). IBV causes an acute highly contagious viral respiratory disease of chickens which is characterized by respiratory rales, coughing and sneezing (**Cavanagh and Nagi, 2003**). Some IBV strains replicate in the gastrointestinal tract, oviduct, and kidney and due to their nephropathogenic properties they have the potential to cause severe losses with up to 44% mortality (**Cavanagh and Nagi, 2003 and Cavanagh, 2005**). In other cases, infection of the proventriculus leads to 75% to 100% mortality in young birds (**Yu et al., 2001**). Many serotypes have been described for IBV due to the nature of coronaviruses that show frequent mutations or recombinations, which easily occur in RNA viruses, leading to novel pathogenic variants (**Gelb et al., 2005 and Wijimenga, 2009**). In most cases, the new isolates have restricted distribution and remain associated with particular geographic areas (**Gelb et al., 2005**). The commonly used IBV attenuated vaccine is H120 while the Mass 41 (M41) strain is commonly used in inactivated vaccines, but in many cases the renal damage was observed in IB vaccinated flocks, suggesting that the currently used IB vaccination procedures may not be providing adequate protection (**Tawifik et al., 2013**). Therefore, efforts are continually being made to identify and characterize field isolates, allowing better understanding of IBV pathogenicity for better disease control. The virion has three major virus-encoded structural proteins, namely the spike (S) glycoprotein, the membrane (M) protein, and the nucleocapsid (N) protein. The spike glycoprotein gene is the most variable gene in the IBV genome (**Jakwood et al., 2010**) and is composed of S1 and S2 subunits. The molecular identification of IBV is based mainly on analysis of the S1 protein gene. The S1 protein is highly variable; it can differ from 20% to 25% and even up to 50% in the amino acid sequence among IBV serotypes (**Cavanagh et al., 2005**). This variability makes the S1 gene an ideal target in molecular assays to type IBV strains by RRT-PCR and sequencing. The real time RRT-PCR assay presented to provide a time-saving, sensitive and reliable method for detection of IBV directly from tracheal or cloacal swabs, as well as in allantoic fluid from infected embryonated eggs (**Meir et al., 2010**). Also, Reverse transcriptase-polymerase chain reaction (RRT-PCR) assays are rapid, specific, and accurate, and when targeting the viral S1 gene, the

amplification products can be used for further classification of the virus (**Lee et al., 2000 and Gelb et al., 2005**). Furthermore, IBV may be detected directly in tissues of infected birds by means of immunohistochemistry (**Chen et al., 1996**) or in situ hybridization (**Collisson et al., 1990**). IBV strains related to the Massachusetts D3128, D274, D-08880 and 4/91 genotypes have been detected at different poultry farms in Egypt (**Sultan et al., 2004 and Abdel-Moneim et al., 2006**). [The Egyptian variant, Egypt/Beni-Suef/01 was isolated from different poultry farms in 2001 and was closely related to the Israeli variant strain]. The Egyptian variant, Ck/Eg/BSU- 1/2011, Ck/Eg/BSU-2/2011, Ck/Eg/BSU- 3/2011, Ck/Eg/BSU-4/2011 Ck/Eg/BSU- 5/2011 strains can be considered a new IBV variant circulating in Egypt these days resembling IBV-isolate –IS-885 strain isolated in Israel (**Abdel-Moneim et al., 2002, Abdel-Moneim et al., 2012**).

This study was conducted to investigate the most prevalent IBV strains in Dakahlia governorate by rapid detection of N gene of IBV by real time RRT-PCR, and then analysis the diversity of the partial part of S1 gene sequences to determine its serotype. Also evaluate the suitability of IHC for detection of IBV antigen in different tissues. This information is important for determining control strategies of IB and improving the efficacy of the vaccines for IBV infection in poultry flocks.

#### **Material and methods**

**Sampling:** Five commercial chicken flocks of varying ages ranging from 28 to 41day, all flocks showed clinical signs of respiratory distress, manifested by sneezing, coughing, tracheal rales, gasping, nasal discharge, head swelling, conjunctival congestion and frothy eyes. Infected chickens were selected. Postmortem examination revealed lesions of inflamed trachea, cheesy exudate in air sacs and enlargement and congestion of the kidneys. Tissue samples from trachea, lungs, spleen, heart and kidneys (4-5 samples per flock) were kept on ice, in sterile transport medium containing 5% antibiotics (20,000 IU/mL penicillin, 10,000 µg/mL streptomycin, and 5000 µg/mL kanamycin) and treated directly for virus detection by RRT-PCR. Also specimens from these organs immediately fixed in 10% neutral buffered formalin for histopathology and immunohistochemistry.

#### **Virus screening with real- time RRT-PCR:**

##### **RNA extraction:**

RNA extraction from samples was done using the QIAamp viral Mini kit (Qiagen, Germany, GmbH). Briefly, 140 µl of the sample suspension was incubated with 560 µl of AVL lysis buffer and 5.6 µl of carrier RNA at room temp. For 10 min. After incubation, 560 µl of 100% ethanol was added to the lysate. The sample was then washed and centrifuged following the manufacturer's recommendations. Nucleic acid was eluted with 60 µl of AE elution buffer provided in the kit.

**Oligonucleotide Primers and probe:**

Primers and probe used were supplied from **Metabion (Germany)** are listed in table (1)

**PCR amplification:**

Primers were utilized in a 25-  $\mu$ l reaction containing 12.5  $\mu$ l of Quantitect probe RRT-PCR kit (Qiagen, Germany, GmbH), 0.5  $\mu$ l of each primer of 50 pmol concentration, 0.125  $\mu$ l of 30 pmol conc. probe, 0.2  $\mu$ l of rt-enzyme, 4.375  $\mu$ l of water and 7  $\mu$ l of RNA template. The reaction was performed and analyzed using a step one real time PCR machine (Applied Biosystem).

**Table (1):** Primers and probe sequences, target genes, amplicon sizes and cycling conditions.

Target gene	Primers sequences	Amplified segment (bp)	Reverse transcription	Primary denaturation	Amplification (40 cycles)	
					Secondary denaturation	Annealing and extension
AIBV -fr	ATGCT CAACC TTGTC CCTAG CA	130	50C 30 min.	94°C 15 min.	94°C 45 sec.	60°C 45 sec.
AIBV -as	TCAAA CTGCG GATCA TCACG T					
AIBV -TM	(FAM- TTGGA AGTAG AGTGA CGCCC AAACT TCA- TAMRA )					

**Sp1 gene sequencing:** Two positive samples by RRT-PCR are used for amplification of a segment of 500-bp of the S1 gene coding region using a primer combination of IB-S1-F and IB-S1-R (**Table 2**). The amplification reaction was carried out with Qiagen one-step RRT-PCR (Qiagen, Inc. Valencia CA) according to the manufacturer's protocol using specific primers for spike gene its sequence as following :-

IBV-S1-F	Forward	5-CAC TGG TAA TTT TTC AGA TGG-3
IBV-S1-R	Reverse	5-C AGA TTG CTT ACA ACC ACC-3

---

Amplification products were analyzed in 1.5% agarose gel. The predicted size of RRT-PCR product was about 400-bp. The RRT-PCR products were cut from the gel and purified using the QIAquick gel extraction kit (Qiagen Inc. Valencia CA) according to the manufacturer's protocol. Purified RRT-PCR products were sequenced in a forward direction using primer IBV-S1-F. Sequencing reactions was done using Bigdye Terminator V3.1 cycle sequencing kit (Perkin-Elmer, Foster city, CA). It was used for performing gene sequencing using an Applied Biosystems 3130 genetic analyzer (ABI, USA).

#### **Phylogenetic analysis:**

To identify the Egyptian IBV isolates, sequences of the Spike gene of the Egyptian IBV isolates were compared with published IBV sequences deposited in the Gene Bank database using a BLAST search via the National Center of Biotechnology Information (USA). Sequence identities by BLAST analysis were included in alignment and phylogenetic construction. A phylogenetic tree of the nucleotide sequences was constructed using MEGA version 4 (**Kumeret et al., 2004**). A comparative analysis of Spike gene sequences was performed using the CLUSTALW Multiple Sequence Alignment Program, version 1.83 (**Ziegler et al., 2002**).

#### **Histopathological study:**

25 Specimens from trachea, lungs, kidneys, heart and spleen were collected from infected birds after post mortem examination and fixed in 10% buffered neutral formalin solution, dehydrated in gradual ethanol (70-100%), cleared in xylene and embedded in paraffin, five micron sections were prepared and then routinely stained with hematoxylin and eosin (H&E) according to Suvarna et al (2013). Then examined microscopically.

#### **Immunohistochemical study:**

The avidin biotin complex immunoperoxidase technique was used as a rapid test to confirm the detection of Ib viral antigen in different organs and tissues obtained from

chicken. Trachea, lungs, kidneys, heart and spleen specimens were collected from positive infected chicken for RRT-PCR.

The technique was applied on paraffin sections using positive slides according to the methods of Suvarna et al (2013).

The primary antibody IB Ab Igg. Prepared in chicken from Gd lap in Netherland while the secondary antibody conjugated with avidinbiotin immunoperoxidase complex (power-stain TsM. 1.0 poly HRPDI kit.

### **Results and discussion**

Infectious bronchitis (IB) is one of most common and difficult control poultry diseases caused persistent but infrequent outbreaks in commercial chicken farms. One of the major problems with IBV is the frequent emergence of new variants. Natural outbreaks of IBV often are the result of infection with strains that differ serologically from vaccine strains. It is imperative to learn profoundly the circulating IBVs, facilitate selecting the candidate vaccine strain against the infections. The clinical examination of all examined flocks in this study showed respiratory signs ranged from mild to sever and complicated chronic respiratory diseases .Some examined flock showed renal signs in form of chalky droppings. These findings were agreed with these observed by **(El-Sisi and Eid-Amal, 2000)**.The postmortem examination revealed lesions of inflamed trachea, cheesy exudate in air sacs and swelling and congestion of the kidneys. These postmortem lesions were similar to that obtained by **(Abd El-Monem et al., 2006 and El-Shafey, 2008)**.

**(Stachowiak et al., 2005)** assessed the feasibility of the N-gene specific RRT-PCR to detect the virus directly in tissues without virus isolation. A real time RRT-PCR targeting N gene was performed on five samples of homogenized tissue pool of lungs, trachea, spleen, heart and kidney of field cases. Four of them were positive for IBV as shown in (Fig 1). This result is agreement with **(Meir et al., 2010)** who stated development of a real time Taqman RRT-PCR targeting the highly conserved nucleocapsid (N) gene of IBV and including an internal PCR control, and the assay was specific for IBV and did not detect other avian pathogens, including turkey coronaviruses.

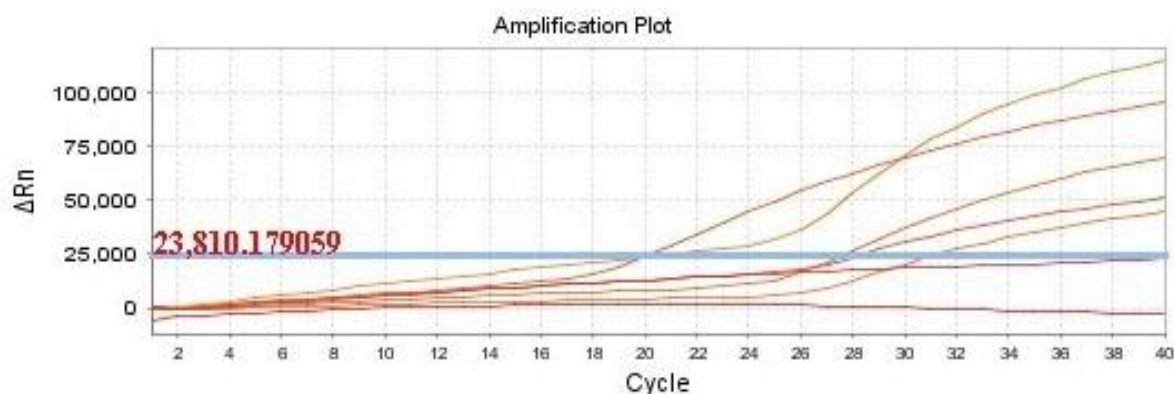


Fig 1: Amplification curves of 5 IBV samples using RRT-PCR

Genotyping of IBV on the basis of the S1 gene sequence, particularly the HVR region of the S1 gene, is the most common way to classify IBV isolates. IBV serotypes commonly differ by 20 to 25% in S1 (Cavanagh et al., 1992), but some serotypes differ in S1 by as little as 2% (Kingham et al., 2000). The most frequently IBV sequences in Gene Bank are localized at S1 gene, which is a part of the IBV genome with high variability. Therefore, it provided obvious possibilities for the construction of strain specific oligonucleotides. Our study was designed to identify incidence of most genotype of IBV. We used oligonucleotides primer designed by Adzhar et al., 1997, which was capable to detect the different genotypes of IBV (Classic and Variant). In the present study, an approximately 400-bp region of S1 gene covering HVR3 were amplified and used for typing the field isolate in Egypt. Two screened positive samples were amplified by RRT-PCR using specific primers for S1 gene, a segment of 400-bp was obtained, The nucleotide and deduced amino acid sequences were determined and compared among each other and with other IBV strains published in the Gene Bank database including vaccinal strains used in Egypt. One was genetically characterized as IBV Variant 2 closely related to Infectious bronchitis virus isolate Eg/12120s/2012 spike glycoprotein (SP1) gene with identity 99% and gene, with identity 96%. The second was genetically characterized as IBV Variant 2 closely related to Infectious bronchitis virus isolate Eg/12120s/2012 spike glycoprotein (SP1) gene with identity 95% and Avian infectious bronchitis virus isolate IS/885 S1 spike glycoprotein gene, identity 93% as show in table (3). Our results are agreement with the concept that IBV mutates commonly and endemic variants 2 is circulating in Egypt (Kawtheret al., 2014). The main problem of the IBV that it has many variants that evolves independent evolution in Egypt and persistence of divergent stains currently circulating in the country (Selim et al., 2013). Moreover, other variants gain access through disease transportation from nearby countries. For example in Libya, (Awad et al., 2014) reported that the variant isolated were with 100% relatedness to Eg/CLEVB-2/IBV/012 and IS/1494/06 (Egyptian variant).

All isolates came from flocks vaccinated with Mass-type H120 which implies insufficient protection against these isolate. The poor relationship in the partial S1 sequence between the two isolates could explain the failure of the vaccination programmes to control IBV in these flocks (Terregino et al., 2008).

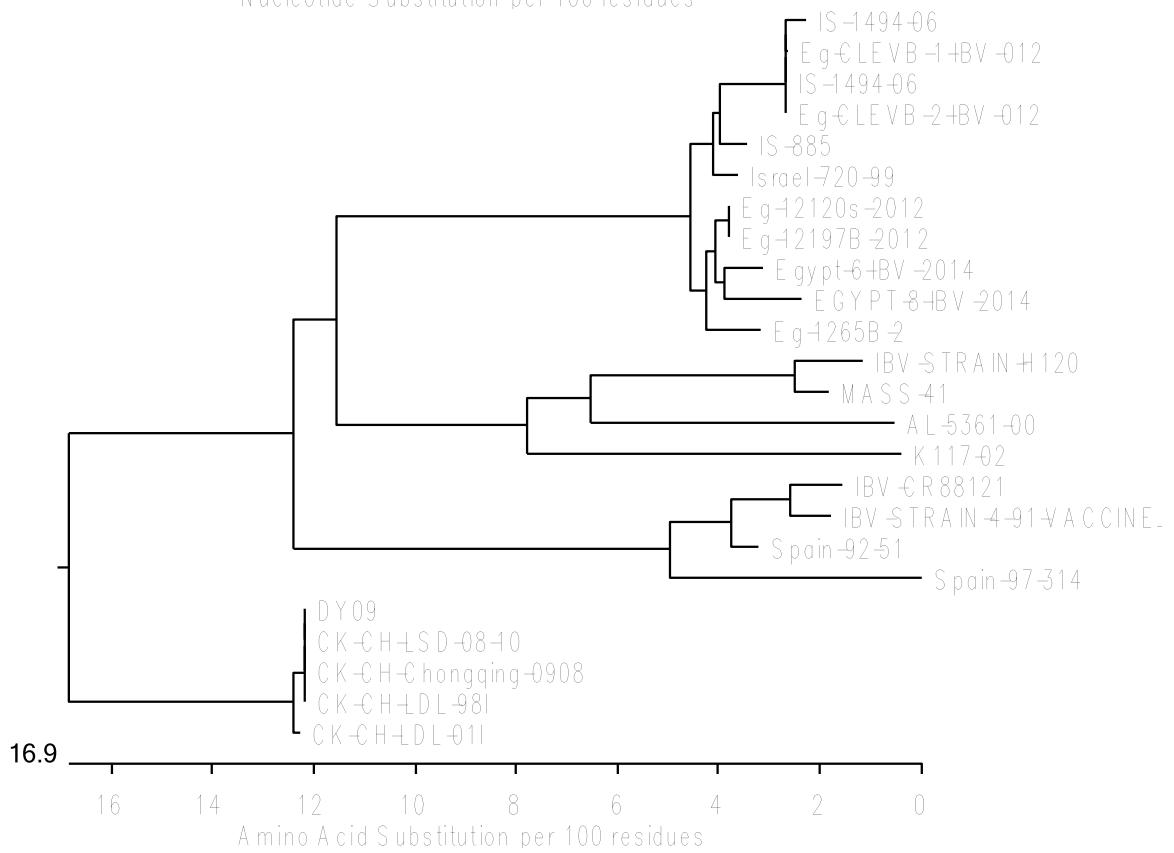
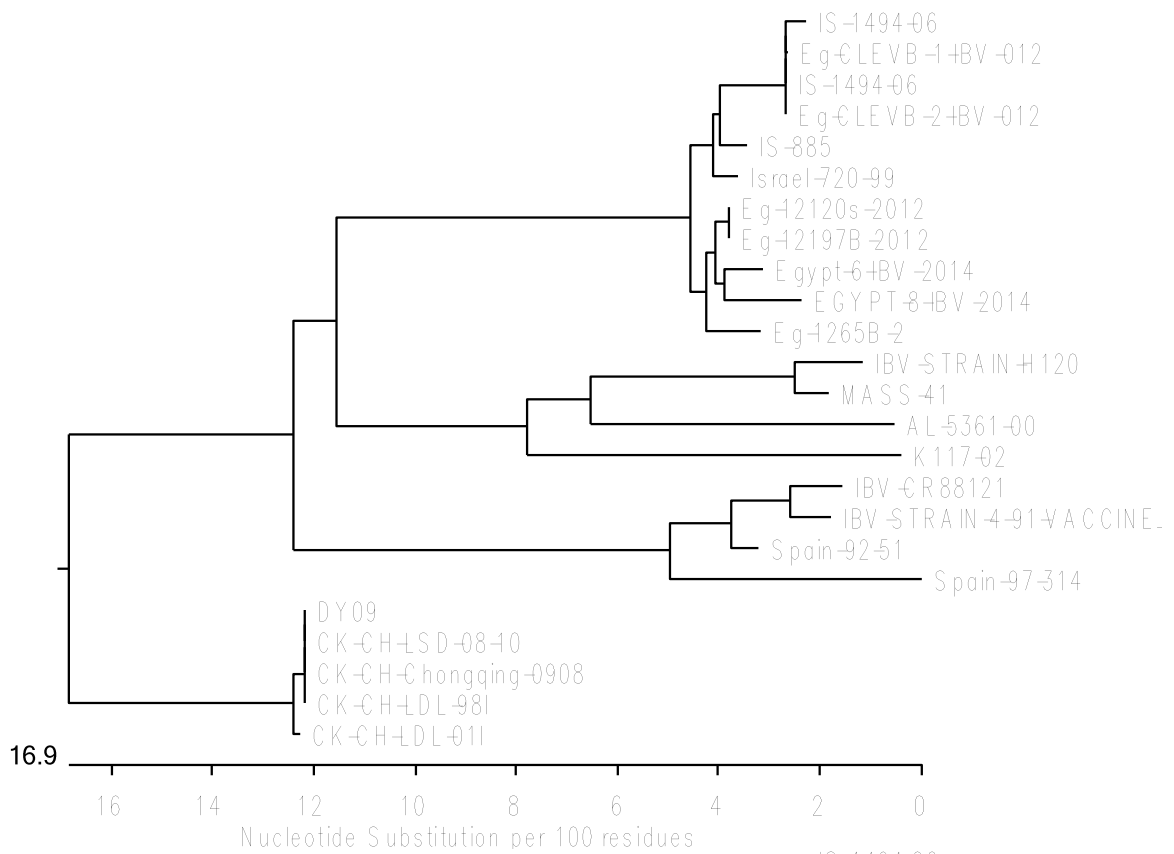
**Table (2):** similarity and divergency percentage % of nucleotide

		Percent Identity																										
		1	2	3	4	5	6	7	8	9	10	11	12	13	14	15	16	17	18	19	20	21	22	23	24			
Divergency	1	0.0	99.4	96.3	95.1	96.3	95.1	98.2	98.2	98.2	84.8	82.9	99.4	96.3	84.8	84.8	84.8	84.8	84.8	87.8	85.4	86.6	84.8	85.4	85.4	1	Eg/12120s/2012	
	2	0.0	100.0	99.4	96.3	95.1	96.3	95.1	98.2	98.2	84.8	82.9	99.4	96.3	84.8	84.8	84.8	84.8	84.8	87.8	85.4	86.6	84.8	85.4	85.4	2	Eg/12197B/2012	
	3	0.6	0.6	100.0	95.7	94.5	95.7	94.5	97.6	97.6	85.4	82.3	98.8	95.7	85.4	85.4	85.4	85.4	85.4	88.4	86.0	87.2	85.4	86.0	86.0	3	Eg/1265B/2	
	4	3.8	3.8	4.4	100.0	98.8	98.8	97.0	97.0	83.5	82.3	95.7	93.3	83.5	83.5	83.5	84.8	87.8	85.4	87.8	85.4	87.8	83.5	86.6	84.1	4	IS/1494/06	
	5	5.1	5.1	5.7	1.2	100.0	98.8	97.6	95.7	95.7	82.3	81.7	94.5	92.1	82.9	82.3	82.3	82.3	84.1	87.2	84.1	87.2	82.9	86.0	83.5	5	IS/1494/06	
	6	3.8	3.8	4.4	0.0	1.2	100.0	98.8	97.0	97.0	83.5	82.3	95.7	93.3	83.5	83.5	83.5	84.8	87.8	85.4	87.8	85.4	87.8	83.5	86.6	84.1	6	Eg/CLEVB-2/IBV/012
	7	3.8	3.8	4.5	0.0	1.3	0.0	100.0	95.7	95.7	82.3	81.1	94.5	92.1	82.3	82.3	82.3	83.5	86.6	84.1	86.6	82.3	82.3	83.5	86.6	84.1	7	Eg/CLEVB-1/IBV/012
	8	1.9	1.9	2.5	3.1	4.4	3.1	3.2	100.0	98.8	84.8	82.9	97.6	95.1	84.8	84.8	84.8	84.8	84.1	87.8	85.4	86.6	83.5	85.4	84.1	8	Israel/720/99	
	9	1.9	1.9	2.5	3.1	4.4	3.1	3.2	1.2	100.0	86.0	83.5	97.6	95.1	86.0	86.0	86.0	86.0	85.4	89.0	86.6	87.8	84.8	86.6	85.4	9	IS/885	
	10	15.8	15.8	15.0	17.3	18.9	17.3	17.6	15.8	14.3	100.0	78.0	85.4	82.9	98.8	100.0	100.0	100.0	82.9	84.8	77.4	83.5	79.3	83.5	79.9	10	D/09	
	11	19.6	19.6	20.4	20.4	21.2	20.4	20.7	19.6	18.8	24.7	100.0	83.5	82.3	78.7	78.0	78.0	78.0	81.7	82.3	84.8	80.5	86.0	80.5	86.6	11	AL/5361/00	
	12	0.6	0.6	1.2	4.4	5.7	4.4	4.5	2.5	2.5	15.0	18.8	100.0	97.0	85.4	85.4	85.4	85.4	88.4	85.4	87.2	84.8	86.0	85.4	12	Egypt/IBV/2014		
	13	3.8	3.8	4.4	7.1	8.4	7.1	7.2	5.1	5.1	18.1	20.4	3.1	100.0	82.9	82.9	82.9	82.9	86.0	83.5	84.8	82.3	83.5	82.9	13	Egypt/IBV/2014		
	14	15.8	15.8	15.0	17.3	18.1	17.3	17.6	15.8	14.3	1.2	23.8	15.0	18.1	100.0	98.8	98.8	98.8	83.5	85.4	77.4	84.1	79.9	84.1	80.5	14	CK/CHLSD/011	
	15	15.8	15.8	15.0	17.3	18.9	17.3	17.6	15.8	14.3	0.0	24.7	15.0	18.1	1.2	100.0	100.0	100.0	82.9	84.8	77.4	83.5	79.3	83.5	79.9	15	CK/CHLSD/08-10	
	16	15.8	15.8	15.0	17.3	18.9	17.3	17.6	15.8	14.3	0.0	24.7	15.0	18.1	1.2	0.0	100.0	100.0	82.9	84.8	77.4	83.5	79.3	83.5	79.9	16	CK/CH/Chongqing/0908	
	17	15.8	15.8	15.0	17.3	18.9	17.3	17.6	15.8	14.3	0.0	24.7	15.0	18.1	1.2	0.0	0.0	82.9	84.8	77.4	83.5	79.3	83.5	79.9	17	CK/CHLSD/98/1		
	18	17.2	17.2	16.4	17.2	18.0	17.2	17.4	18.0	16.4	18.1	21.2	16.4	19.6	17.3	18.1	18.1	18.1	90.2	80.5	89.6	78.7	89.0	79.3	18	Spain/973/14		
	19	13.4	13.4	12.7	13.4	14.2	13.4	13.6	13.4	12.0	15.8	20.4	12.7	15.7	15.0	15.8	15.8	10.5	82.9	97.6	81.7	96.3	82.3	19	Spain/92/51			
	20	16.4	16.4	15.7	16.4	18.0	16.4	16.7	16.4	14.9	25.5	17.2	16.4	18.8	25.5	25.5	25.5	25.5	22.8	19.6	81.7	87.8	80.5	88.4	20	K117-02		
	21	14.2	14.2	13.4	12.7	13.4	12.7	12.9	14.2	12.7	18.0	22.0	13.4	16.4	17.2	18.0	18.0	10.5	1.9	20.4	81.1	97.6	81.7	21	IBV-CR88121			
	22	16.4	16.4	15.7	18.0	18.8	18.0	18.2	18.0	16.4	23.7	14.9	16.4	19.6	22.8	23.7	23.7	23.7	24.5	20.4	12.7	21.8	79.9	98.8	22	IBV-STRAIN-H120		
	23	15.7	15.7	14.9	14.2	14.9	14.2	14.4	15.7	14.2	18.0	22.0	14.9	18.0	17.2	18.0	18.0	11.3	3.1	22.0	2.5	23.5	80.5	23	IBV-STRAIN-4/91-VACCINE			
	24	15.7	15.7	14.9	17.2	18.0	17.2	17.4	17.2	15.7	22.8	14.2	15.7	18.8	22.0	22.8	22.8	22.8	23.7	19.6	12.0	21.0	1.2	22.7	24	MASS-41		
	1	2	3	4	5	6	7	8	9	10	11	12	13	14	15	16	17	18	19	20	21	22	23	24				

Similarity and divergency percentage% of amino acids

		Percent Identity																										
		1	2	3	4	5	6	7	8	9	10	11	12	13	14	15	16	17	18	19	20	21	22	23	24			
Divergency	1	0.0	99.4	96.3	95.1	96.3	95.1	98.2	98.2	84.8	82.9	99.4	96.3	84.8	84.8	84.8	84.8	84.8	87.8	85.4	86.6	84.8	85.4	85.4	1	Eg/12120s/2012		
	2	0.0	100.0	99.4	96.3	95.1	96.3	95.1	98.2	98.2	84.8	82.9	99.4	96.3	84.8	84.8	84.8	84.8	84.8	87.8	85.4	86.6	84.8	85.4	85.4	2	Eg/12197B/2012	
	3	0.6	0.6	100.0	95.7	94.5	95.7	94.5	97.6	97.6	85.4	82.3	98.8	95.7	85.4	85.4	85.4	85.4	88.4	86.0	87.2	85.4	86.0	86.0	3	Eg/1265B/2		
	4	3.8	3.8	4.4	100.0	98.8	98.8	97.0	97.0	83.5	82.3	95.7	93.3	83.5	83.5	83.5	84.8	87.8	85.4	87.8	85.4	87.8	83.5	86.6	84.1	4	IS/1494/06	
	5	5.1	5.1	5.7	1.2	100.0	98.8	97.6	95.7	95.7	82.3	81.7	94.5	92.1	82.9	82.3	82.3	84.1	87.2	84.1	87.2	82.9	86.0	83.5	5	IS/1494/06		
	6	3.8	3.8	4.4	0.0	1.2	100.0	98.8	97.0	97.0	83.5	82.3	95.7	93.3	83.5	83.5	83.5	84.8	87.8	85.4	87.8	85.4	87.8	83.5	86.6	84.1	6	Eg/CLEVB-2/IBV/012
	7	3.8	3.8	4.5	0.0	1.3	0.0	100.0	95.7	95.7	82.3	81.1	94.5	92.1	82.3	82.3	82.3	83.5	86.6	84.1	86.6	82.3	82.3	83.5	86.6	84.1	7	Eg/CLEVB-1/IBV/012
	8	1.9	1.9	2.5	3.1	4.4	3.1	3.2	100.0	98.8	84.8	82.9	97.6	95.1	84.8	84.8	84.8	84.8	84.1	87.8	85.4	86.6	83.5	85.4	84.1	8	Israel/720/99	
	9	1.9	1.9	2.5	3.1	4.4	3.1	3.2	1.2	100.0	86.0	83.5	97.6	95.1	86.0	86.0	86.0	86.0	85.4	89.0	86.6	87.8	84.8	86.6	85.4	9	IS/885	
	10	15.8	15.8	15.0	17.3	18.9	17.3	17.6	15.8	14.3	100.0	78.0	85.4	82.9	98.8	100.0	100.0	100.0	82.9	84.8	77.4	83.5	79.3	83.5	79.9	10	D/09	
	11	19.6	19.6	20.4	20.4	21.2	20.4	20.7	19.6	18.8	24.7	100.0	83.5	82.3	78.7	78.0	78.0	78.0	81.7	82.3	84.8	80.5	86.0	80.5	86.6	11	AL/5361/00	
	12	0.6	0.6	1.2	4.4	5.7	4.4	4.5	2.5	2.5	15.0	18.8	100.0	97.0	85.4	85.4	85.4	85.4	88.4	85.4	87.2	84.8	86.0	85.4	12	Egypt/IBV/2014		
	13	3.8	3.8	4.4	7.1	8.4	7.1	7.2	5.1	5.1	18.1	20.4	3.1	100.0	82.9	82.9	82.9	82.9	86.0	83.5	84.8	82.3	83.5	82.9	13	Egypt/IBV/2014		
	14	15.8	15.8	15.0	17.3	18.1	17.3	17.6	15.8	14.3	1.2	23.8	15.0	18.1	100.0	98.8	98.8	98.8	83.5	85.4	77.4	84.1	79.9	84.1	80.5	14	CK/CHLSD/011	
	15	15.8	15.8	15.0	17.3	18.9	17.3	17.6	15.8	14.3	0.0	24.7	15.0	18.1	1.2	100.0	100.0	100.0	82.9	84.8	77.4	83.5	79.3	83.5	79.9	15	CK/CHLSD/08-10	
	16	15.8	15.8	15.0	17.3	18.9	17.3	17.6	15.8	14.3	0.0	24.7	15.0	18.1	1.2	0.0	100.0	100.0	82.9	84.8	77.4	83.5	79.3	83.5	79.9	16	CK/CH/Chongqing/0908	
	17	15.8	15.8	15.0	17.3	18.9	17.3	17.6	15.8	14.3	0.0	24.7	15.0	18.1	1.2	0.0	0.0	82.9	84.8	77.4	83.5	79.3	83.5	79.9	17	CK/CHLSD/98/1		
	18	17.2	17.2	16.4	17.2	18.0	17.2	17.4	18.0	16.4	18.1	21.2	16.4	19.6	17.3	18.1	18.1	18.1	90.2	80.5	89.6	78.7	89.0	79.3	18	Spain/973/14		
	19	13.4	13.4	12.7	13.4	14.2	13.4	13.6	13.4	12.0	15.8	20.4	12.7	15.7	15.0	15.8	15.8	10.5	82.9	97.6	81.7	96.3	82.3	19	Spain/92/51			
	20	16.4	16.4	15.7	16.4	18.0	16.4	16.7	16.4	14.9	25.5	17.2	16.4	18.8	25.5	25.5	25.5	25.5	22.8	19.6	81.7	87.8	80.5	88.4	20	K117-02		
	21	14.2	14.2	13.4	12.7	13.4	12.7	12.9	14.2	12.7	18.0	22.0	13.4	16.4	17.2	18.0	18.0	10.5	1.9	20.4	81.1	97.6	81.7	21	IBV-CR88121			
	22	16.4	16.4	15.7	18.0	18.8	18.0	18.2	18.0	16.4	23.7	14.9	16.4	19.6	22.8	23.7	23.7	23.7	24.5	20.4	12.7	21.8	79.9	98.8	22	IBV-STRAIN-H120		
	23	15.7	15.7	14.9																								





**Fig 2:**Phylogenetic analysis show that both samples are very closely related to Infectious bronchitis virus isolate Eg/1212s/2012

Alignment Report of amino acids of 2examined samples with different strains from gene bank  
 Majority  
 ETINNGLWFNSLSVSLAYGPLQGGCKQSVFNNRATCCYAYSYNGPRLCKGVYX  
 GELQQYFECGLLVYVTKSDGSRIQTRN

	10	20	30	40	50	60	70	80
Eg/12120s/2012					T		G	
Eg/12197B/2012					T		G	
Eg/1265B/2					T		G	
IS/1494/06			S		I			
IS/1494/06			S		I	P	I	
Eg/CLEVB-2/IBV/012			S		I			
Eg/CLEVB-1/IBV/012		XX		S		I		
Israel/720/99		P			T			
IS/885					T			
DY09		G	M	S	T	S	Q	KT
AL/5361/00		IT		QGK		V	SHA	S
Egypt/6/IBV/2014					T		G	
EGYPT/8/IBV/2014					T		NNV	
CK/CH/LDL/01I		G	M	S	T	S	KKT	F
CK/CH/LSD/08-10		G	M	S	T	S	Q	KT
CK/CH/Chongqing/0908		G	M	S	T	S	Q	KT
CK/CH/LDL/98I		G	M	S	T	S	Q	KT
Spain/97/314	N	T	I	S	TK	T	FSRD	I
Spain/92/51	N	T	I	S	Q	TR	R	N
K117-02		I	SS		A	A	S	L
IBV-CR88121	N	T	I	S	Q	SR	R	T
IBV-STRAIN-H120		I	SG	G	L	S	DHN	G
IBV-STRAIN-4/91-VACCINE		N	T	I	S	K	R	TR
MASS-41		I	SG	E	L	S	DHN	G

Majority

EPLVLTQHNYNNITLNKCVEYNIYGRVGGFITNVTXSAANYNYLADGGLAIL  
 DTSGAIDIFVVQGEYGLNYYKVNPCED

	90	100	110	120	130	140	150	160
Eg/12120s/2012	.....H.....	DR.....	F.....				P.....	
Eg/12197B/2012	.....H.....	DR.....	F.....				P.....	
Eg/1265B/2	.....H.....	DR.....	F.....					
IS/1494/06	.....HY.....	DR.....	S.....	I.....			P.....	
IS/1494/06	.....HY.....	DR.....	S.....	I.....			P.....	
Eg/CLEVB-2/IBV/012	.....HY.....	DR.....	S.....	I.....			P.....	
Eg/CLEVB-1/IBV/012	.....HY.....	DR.....	S.....	I.....			P.....	
Israel/720/99	.....H.....	DR.....	S.....				P.....	
IS/885	.....H.....	R.....	S.....				P.....	
DY09				L..ID..	HG.....	V.....	V.....	V..T.....
AL/5361/00	..P.I.....	H.....	T.....	SS..E.....			TH.P.....	
Egypt/6/IBV/2014	.....H.....	D.....	F.....				P.....	
EGYPT/8/IBV/2014	.....H.....	D.....	F.....	Y..S.....			P.....	
CK/CH/LDL/01I				L..ID..	HG.....	V.....	V.....	V..T.....
CK/CH/LSD/08-10				L..ID..	HG.....	V.....	V.....	V..T.....
CK/CH/Chongqing/0908				L..ID..	HG.....	V.....	V.....	V..T.....
CK/CH/LDL/98I				L..ID..	HG.....	V.....	V.....	V..T.....
Spain/97/314	.....Y.....	F.....	A..G.....			T....	SH.....	
Spain/92/51				AT..S.....			A.....	
K117-02	..P.I.....	T.D.....	IR.....	SSS....	A.....		H.....	
IBV-CR88121	.....Y.....			EAT..S.....			A.....	
IBV-STRAIN-H120	..P.I.....	T.D.....	T.....	D.VS....	A.....	S.....	S.....	
IBV-STRAIN-4/91-VACCINE	.....Y.....	EAT..S.....		R.A.....				
MASS-41	..P.I.....	T.D.....	T.....	D.VS....	A.....	S.....		

Regarding, histopathological changes of RRT-PCR positively infected trachea, lungs, kidneys, spleen and heart with IBV were reported. The microscopical findings of the trachea showed intense Catarrhal tracheitis with mucous exudate inside the tracheal lumen was common. Loss of cilia, thickened mucosa by hyperemia, desquamation of epithelial cells and Infiltration of heterophils and lymphocytes could be seen (Figs 3and 4). These results agreed with that obtained by **(Saif et al., 2008)** who mentioned lesions in trachea were edematous mucosa ,loss of cilia ,and rounding with sloughing of epithelial cells. Lungs showed caseous plug inside the primary bronchus surrounded by intense bronchitis and focal pneumonia were common (Fig 5and 6). The later characterized by focal replacement of air vesicles by intense lymphocytic aggregation. The wall of primary bronchus showed intense desquamation with thickening by edema, lymphocytic infiltration and partial necrosis of their smooth muscles. These results proved the epitheliotropic nature of IBV **(Mohammed et al., 2012 and Abdel-Mageed, 2015)** who mentioned lymphocytic infiltration was found inside the parabronchial lumen.

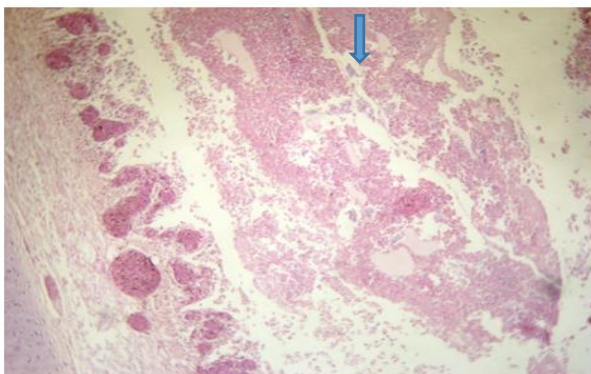
Air sac showed thickening by serofibrinous exudate or round cell aggregations contains hyperplastic epithelial cells were seen (Fig7). Later on, air sac edema, epithelial desquamation, heterophils infiltration or lymphocytic nodules and fibroblastic proliferation and adhesions could be seen. Spleen showed multi focal coagulative necrosis, numerous hemosiderin pigment and intense lymphoid depletion were common (Fig8). Proliferation of reticuloendothelial cells was observed. Kidneys showed interstitial nephritis characterized by necrotic renal tubules replaced by lymphocytic infiltration, edema and hemorrhage accompanied with glomerulitis were common (Fig9). Degeneration and desquamation of tubular epithelium with massive heterophils infiltration could be seen. Lumina of some necrotic collecting renal tubules containing renal casts. Heart showed thickening of pericardium with leukocytic infiltration and serofibrinous exudates (pericarditis) accompanied by inter and intra muscular edema of some myocardial muscle fibers were common (Fig10). These findings are matched with that recorded with **(Albassam et al., 1986, Starciuc et al., 2012 and Bijanzad et al., 2013)**

IBV viral antigen was detected by Avidin biotin complex Immunoperoxidase technique in trachea, lungs, spleen, heart and kidneys from infected chickens. In lungs the viral antigen was detected in the wall of alveoli, in the endothelial lining of blood capillaries and inside blood vessels as shown in (Figs. 11& 12). Also, the antigen was detected in the secondary bronchi as shown in (Figs. 13 &14) These results were agreed with **(Abdel-Moneim et al., 2009 and Fatima, et al. 2012)** .The later reported the initial target of IB virus in chicken is the respiratory epithelium. In trachea viral antigen was detected in the mucosal epithelium and the wall of blood vessels and inside blood vessels as shown in (Figs.15& 16). In kidneys viral antigen was detected in epithelial lining renal tubules and in the wall of renal blood vessels and capillaries as shown in (

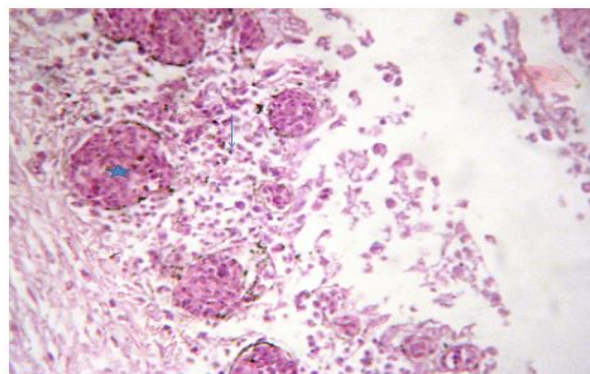
Figs. 17&18).In heart viral antigen was detected in endothelial lining blood capillaries and in between the muscle fibers as shown in (Figs.19& 20). The immunohistochemical findings in these organs in this study are similar to those described previously on other strains of IBV (**Kapczynskiet al., 2002; Abdel-Moneim et al., 2009 and Benyeda et al., 2010**). This finding further confirmed the results of histopathology and RRT-PCR infected tissues. Also, indicated that IBV virus spread via viremia to the affected organs. Therefore, tissue tropism cannot be determined by virus isolation only but required more advanced technique (IHC) which is high sensitive and specific.

### Conclusions

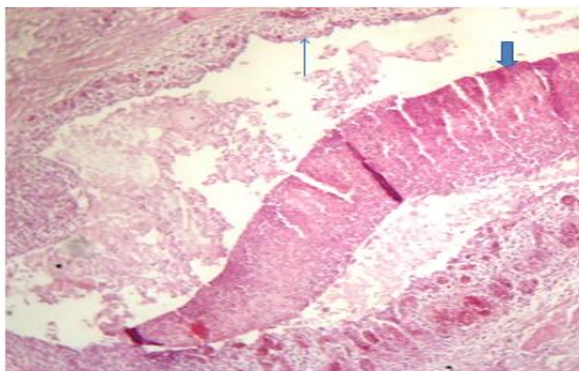
Prevention of IB in chicken is based mainly on vaccination against the virus. Strain H120 of IBV has been used for a long time in broiler chicken flocks to achieve this goal. A vaccination program against IB fails when new strains of IBV emerge in a geographical region. Therefore, routinely monitoring of the existing IBV strains in a geographical region has been suggested to choose a suitable virus strain for vaccination of the IBV disease in Egypt. IHC is an additional tool for diagnosis of IBV infection in chickens and allow further studies to a deeper understanding of the pathogenesis of infections with IBV strains of different virulence .Moreover, guide us for the best vaccines selection and improve control of IBV virus.



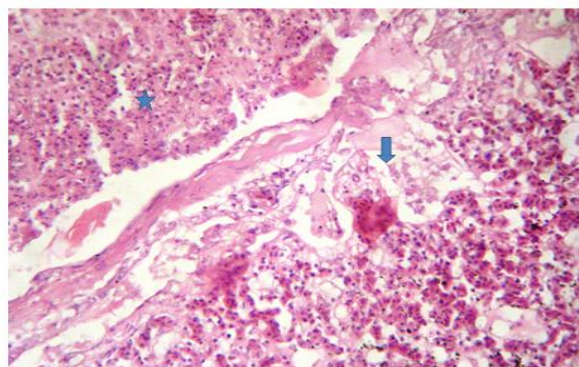
**Fig.3:-**Trachea of chicken Showing catarrhal exudate in tracheal lumen with necrotic epithelium (arrow) and submucosal congestion and leukocytic infiltration. H&E (X100).



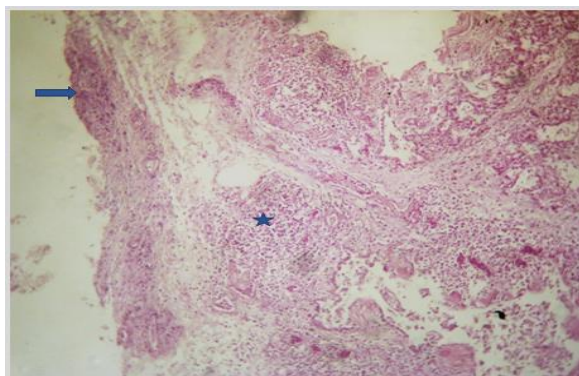
**Fig.4:-**High power of the previous figure:to show massive necrotic epithelium inside tracheal lumen with submucosal congestion (star), lymphocytes and heterophilic infiltration and edematous muscular coats. H&E (X200).



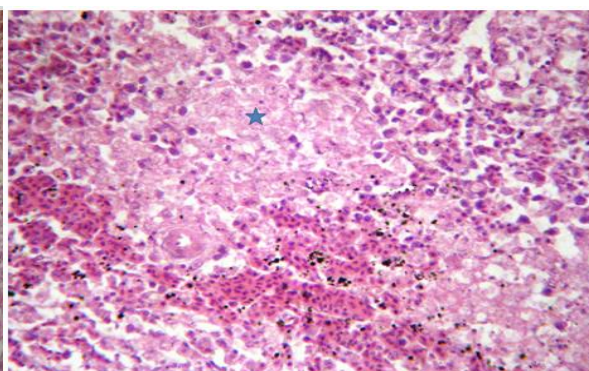
**Fig.5:-** Lung of chicken: showing caseous plug (thick arrow) inside primary bronchus with intense bronchitis (thin arrow). H&E (X100).



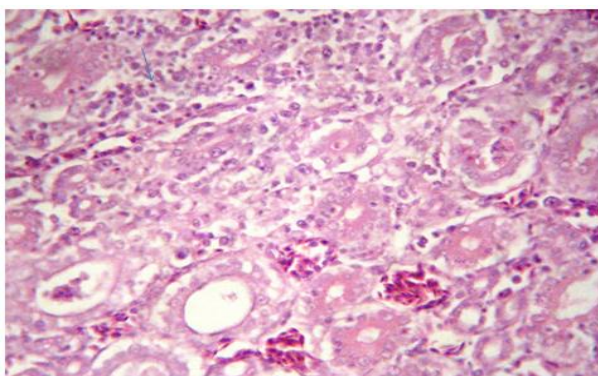
**Fig.6:-**High power of previous figure showing mucous exudates mixed with living and dead heterophils within the bronchial lumen (star) accompanied by intense leukocytic infiltration, edema of bronchial wall and necrosis of bronchial epithelium (arrow).H&E (X200).



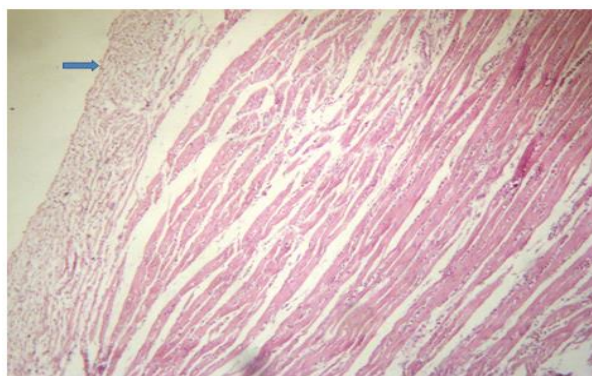
**Fig7:- Lung of chicken:** showing adhesion and thickening of air sacs by edema and inflammatory cells (arrow) with focal lymphocytic pneumonia (star) and bronchitis (head arrow). H&E (X 100).



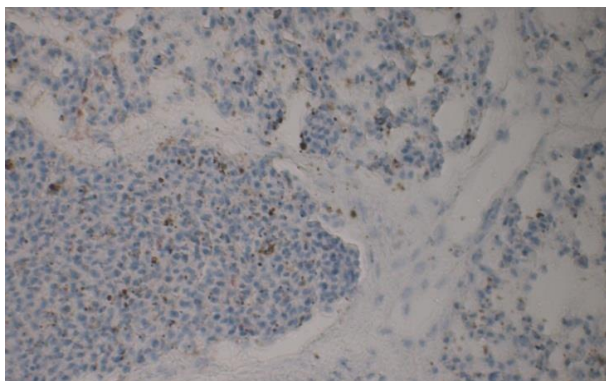
**Fig.8:-** Spleen of chicken showing multifocal coagulative necrosis (stars) and some hemosiderin pigment (arrow) besides lymphoid depletion. H&E (X200).



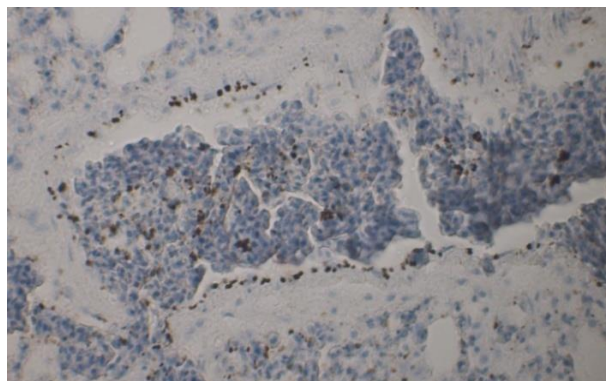
**Fig.9:-** Kidney of chicken showing interstitial nephritis with inflammatory cells infiltrations (thin arrow) and necrotic renal tubules (thick arrow), congested blood vessels. H&E (X 200).



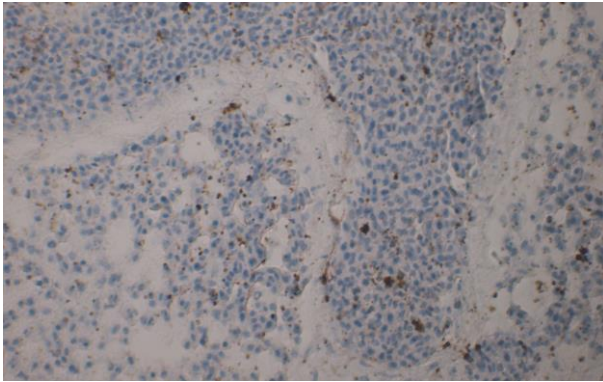
**Fig.10:-** Heart of chicken: showing thickening and inflammation in pericardium by serofibrinous exudate (arrow) (pericarditis) and intramuscular edema. H&E (X 100).



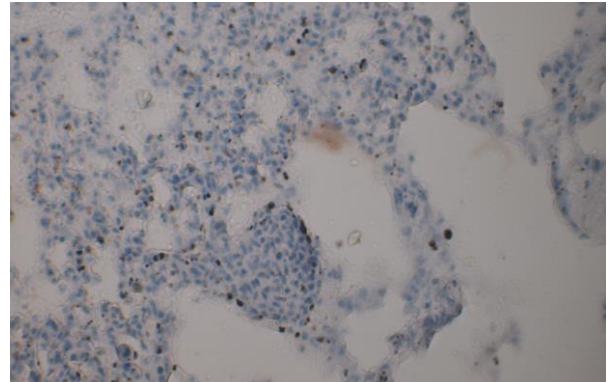
**Fig.11:-** lung of chicken reveal positive reaction appeared as dense brown granules against the wall of alveoli, endothelial lining blood capillaries and inside blood vessels. Avidin biotin immunoperoxidase complex counter stain hematoxylin. (x 200).



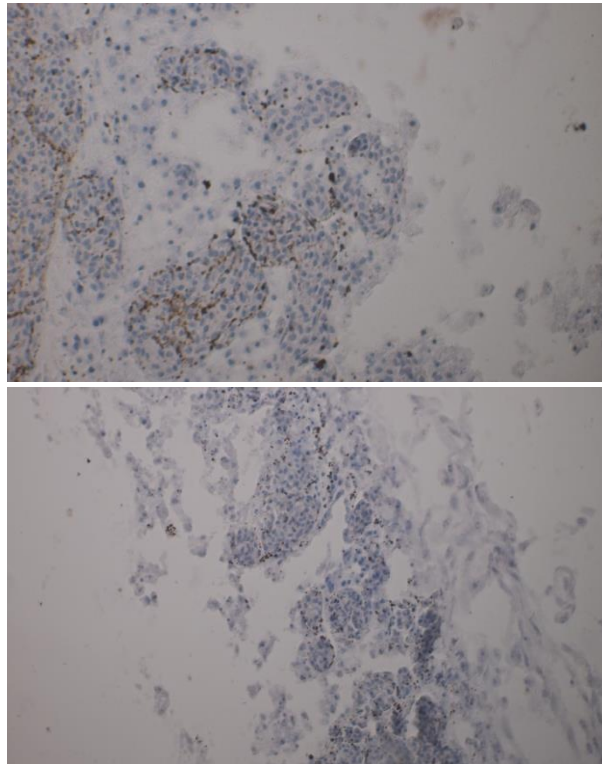
**Fig.12:-** lung of chicken revealing dense brown granules in the endothelial lining of pulmonary blood vessels and within the blood vessels. Avidin biotin immunoperoxidase counter stain hematoxylin. (x200).



**Fig.13:-**Lung of chicken revealing positive reaction against IB viral antigen in the alveolar wall and within pulmonary blood vessels. Avidin biotin immunoperoxidase complex counter stain hematoxylin (x400).

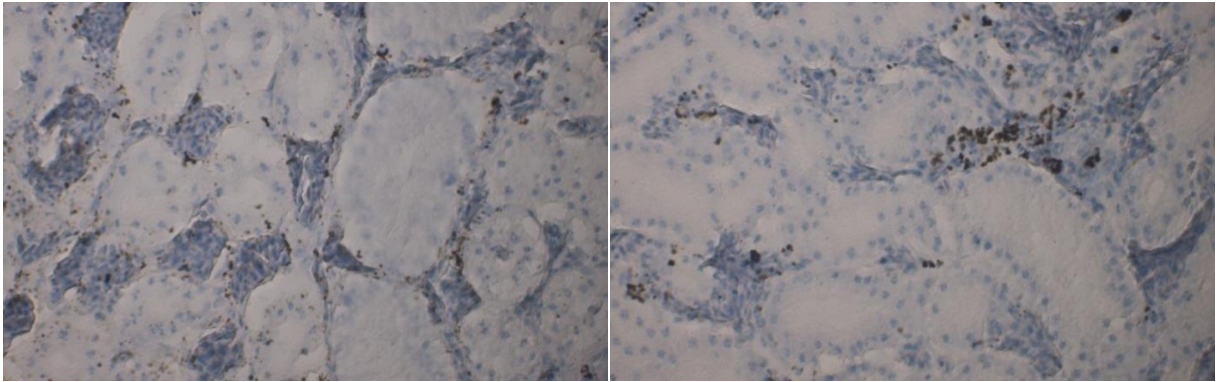


**Fig.14:-**Lung of chicken showing positive reaction in the secondary bronchi. Avidin biotin immunoperoxidase complex counter stain hematoxylin (x400).



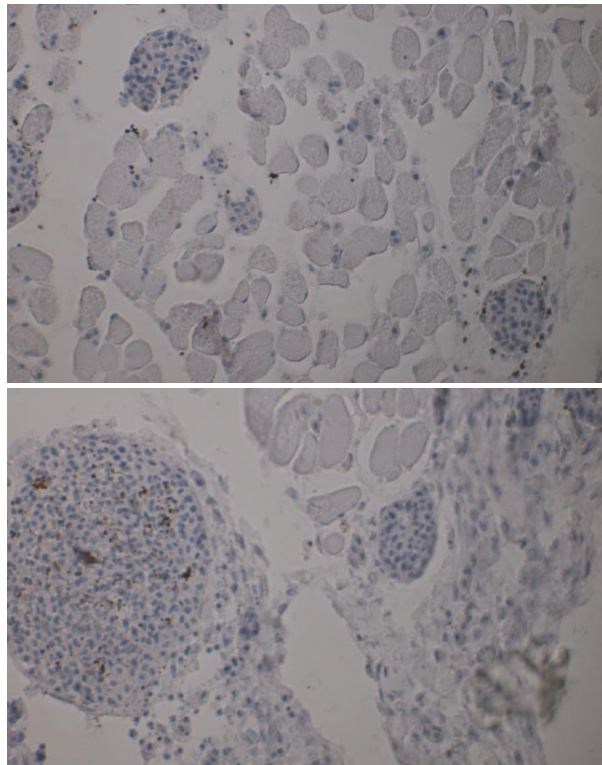
**Figs.15&16:-**Trachea of chicken showing dense brown granules (positive reaction) against IB viral antigen in the mucosal epithelium and the wall of blood vessels inside the blood vessels. . Avidin biotin immunoperoxidase complex counter stain hematoxylin (x400) and (x200).





**Fig.17:-**Kidney of chicken showing moderate positive reaction against IB viral antigen appear as dense brown granules in the wall of renal blood capillaries. Avidin biotin immunoperoxidase complex counter stain hematoxylin (x400).

**Fig18:** Kidney of chicken showing positive reaction against IB viral antigen in the lining tubular epithelium and in the blood vessels Avidin biotin immunoperoxidase complex counter stain hematoxylin. (x200).



**Figs.19&20:-**Heart of chicken showing mild positive reaction against IB viral antigen in the endothelial lining blood capillaries and in between the muscle fibers. Avidin biotin immunoperoxidase complex counter stain hematoxylin (x200) and (x400).

## References

**Abdel-Megeed, H.S.A. (2015):** Pathological and molecular studies on some respiratory infections in chicken at Dakahlia governorate. PH.D. Thesis Mansoura university.

**Abdel-Moneim, A.S.; Afifi, M.A. and El-Kady, M.F. (2012):** Emergence of a novel genotype of avian infectious bronchitis virus in Egypt. *Arch Virol*, 157:2453–2457.

**Abdel-moneim, A.S.; Madbouly, H.M.; Gelb, J.R. and Ladman, B.S. (2002):** Isolation and identification of Egypt/Beni-Suef/01 a novel genotype of infectious bronchitis virus. *VetMed J Giza*, 50: 1065-1078.

**Abdel-Moneim, A.S; El-Kady, M .F; Ladman, B.S . And Gelb, J. Jr. (2006):** S1 gene sequence analysis of a nephro-pathogenic strain of avian infectious bronchitis virus in Egypt. *Virology J*, 3:78.

**Abdel-Moneim, A. S. ; Zlotowski, P.; Veits, J.; Keil, G. M. and Tweifke, J. P. (2009):** Immunohistochemistry for detection of avian infectious bronchitis virus strain M41 in the proventriculus and nervous system of experimentally infected chicken embryos, *Virology Journal*, vol. 6, article 15, pp. 1–7.

**Adzhar, A.; Shaw, K.; Britton, P. and Cavanagh D. (1997):** Molecular analysis of the 793/B serotype of infectious bronchitis virus in Great Britain. *Avian pathology*. 26, 625-640.

**Albassam, M.A.; Winterfield, R.W. And Thacker, H.L. (1986):** Comparison of the nephropathogenicity of four strains of infectious bronchitis virus. *Avian Diseases* 30,

**Awad, F.; Baylis, M. and Ganapathy, K. (2014):** Detection of variant infectious bronchitis viruses in broiler flocks in Libya. *International Journal of Veterinary Science and Medicine*. *International Journal of Veterinary Science and Medicine* (2014) 2, 78–82

**Benyeda, Z.; Szeredi, L.; Mató, T., Süveges, T.; Balka, G.; Abonyi-Tóth, Z., Rusvai, M. and Palya, V., (2010):** Comparative histopathology and immunohistochemistry of QX-like, Massachusetts and 793/B serotypes of infectious bronchitis virus infection in chickens, *Journal of Comparative Pathology* 143, 276–283.

**Bijanzad P., Momayez R., Bozorgmehrifard M.H., Hablolvarid M.H. and Pourbakhsh S.A. (2013):** Experimental study on histopathological changes and tissue tropism of Iranian infectious bronchitis serotype 793/B-like virus in SPF chickens. *J. South Afr. Vet. Assoc.*, 84(1). Available at <http://dx.doi.org/10.4102/jva.v84i1.970>.

**Cavanagh D.;Picault.J. P.; Gough,R. E.; HessM.;Mawditt,K. and Britton ,(2005)P.:** Variation in the spike protein of the 793/B type of infectious bronchitis virus, in the field and during alternate passage in chickens and embryonated eggs.*Avian Pathology*,vol. 34, no. 1, pp. 20–25,.

**Cavanagh, D. (2005):** Coronaviruses in poultry and other birds. *Avian Pathol*, 34:439-448.

**Cavanagh, D. and Gelb, J., ( 2008 ):** Infectious bronchitis, in Y.M. Saif, A.M. Fadly, J.R. Glisson, L.R. McDougald, L.K. Nolan and D.E. Swayne (eds.), *Diseases of poultry*, p. 117–135, Wiley-Blackwell, Ames.

**Cavanagh, D. and Naqi, S. (2003):** Infectious bronchitis. In *Diseases of Poultry* 11th edition. Edited by: Saif YM, Barnes HJ, Glisson JR, Fadly AM, McDougald LR, Swayne DE. Ames: Iowa State University Press; 101-119.

**Cavanagh, D.; Davis, P.J.; Cook J .KA, et al.( 1992):** Location of the amino acid differences in the S1 spike glycoprotein subunit of closely related serotypes of infectious bronchitis virus. *Avian Pathol*. 21: 33–34.

**Chen, BY;Hosi, S.;Nunoya, T .andItakura, C. (1996):** Histopathology and immunohistochemistry of renal lesions due to infectious bronchitis virus in chicks. *Avian Pathol*, 25:269-283.

**Collisson, EW; Li J.; Sneed, LW.; Peters,ML.and Wang, L.(1990):** Detection of avian infectious bronchitis using in situ hybridization and recombinant DNA. *Vet Microbiol*24:261-271.

**El-Mahdy, S.S.,Ekram,S., and Amal,A.(2012):** Efficacy of some living classical and varrient infectious bronchitis vaccines against local varrient isolated from Egypt.Nature and Sci,10(12).

**EL-Shafey,A.M. (2008):**Advanced study on infectious bronchitis of chicken in Egypt. Ph .D.Thesis of Poultry Diseases, Fac.Vet.Med.Zag.Univ.

**El-Sisi, M.A. and Eid-Amal, A.M. (2000):** Infectious bronchitis virus and Infectious bursal disease; concurrent infection among broilers in Egypt .ZagazigVet.J. 28; 150-153.

**Ftima,R.F.J.,Macros,A.Z.M.,Paulo,A.E.,Lara,M.T.,Virginia,S.S.,Cintia,H.O.,Tania , A.P.K.,Alessandra,D.S.,Giseli,R.,and Lina, B.(2012) :**Standarization of immunohistochemistry for detection of avian infection bronchitis. Embrapa Lab Ex EUA de Sanidada Animal 28-30 de Agosto de 2012.

**Gelb, J. Jr., Weismann, Y. and Ladman, B .S. (2005):** S1 gene characteristics and efficacy of vaccination against bronchitis virus field isolates from the United States and Israel (1996 to 2000). *Avian Pathol*. 34:194–203

**Gelb, Jr., J. (2002):** Nephropathogenic infection bronchitis in Pennsylvania chickens \_ 2000. *Avian Disease*, 46, 847 \_ 858.

**Jackwood M.W., T. O. Boynton, D. A. Hilt et al (2010):** Emergence of a group 3 coronavirus through recombination. *Virology*, vol. 398, no. 1, pp. 98–108,.

**Kapczynski ,D.R.,Sellers H.S.,Rowland,G.N.andJackwood,M.W.( 2002) :**Detection of in ovo-inoculated infectious bronchitis virus by immunohistochemistry and in situ hybridization with ariboprobe in epithelial cells of the lung and cloacal bursa.*Avian Dis.* :Jul-Sep;46(3)67985.

**Kawther S. Zaher and 2Zeinab M.S. Amin Girh (2014):** Concurrent Infectious Bronchitis and Newcastle Disease Infection in Egypt. *British Journal of Poultry Sciences* 3 (1): 01-05.

**King, A.M.Q., Adams, M.J., Carstens, E.B. and Lefkowitz, E.J. (eds.), (2012):** *Virus taxonomy – Ninth report of the International Committee on Taxonomy of Viruses*, Elsevier, London.

**Kingham BF, Keeler CL, Nix WA, Ladman BS and Gelb J Jr(2000):** Identification of avian infectious bronchitis virus by direct automated cycle sequencing of the S-1 gene .*Avian Dis*, 44:325-335.

**Kumar, S.,Tamura ,K. and Nei ,M. (2004):**MEGA3 :Integrated software for Molecular EvolutionaryGenetics Analysis and sequence alignment .*Brief Bioinformatics*.5,150-163.

**Lee, C.W., Hilt, D.A. andJackwood, M.W. (2000):** Redesign of primer and application of thereverse transcriptase-polymerase chain reaction and restriction fragment length polymorphism test to the DE072 strain of infectious bronchitis virus. *Avian Dis*. 44, 650–654.

**Meir, R., Maharat, O., Farnushi, Y. and Simanov, L. (2010):** Development of a real timeTaqMan® RT-PCR assay for the detection of infectious bronchitis virus in chickens, and comparison of RT-PCR and virus isolation. *Journal of Virological Methods*, 163: 190–194.

**Mohammed M.H., Hair-Bejo M., Zahid A., Alazawy A., Abdul Ahad E.A. and Hasoon M.F. (2012):** Pathogenesis of infectious bronchitis virus in infected broiler chickens. *Bas. J. Vet. Res.*, 11 (1).

**Saif, Y.M., Fadly, A.M., Glisson, J.R.,Mc Dougald, L.R., Nolanl, K.and Swayne, D.E.2008:** *Deseases of poultry*. 12th Ed,chap (4) infectious bronchitis .pp:117-135.

**Selim, K., A.S. Arafa, H.A. Hussein, A.A. El-, Z., I. Yougbaré, A. Kam, M.C. Tahita and Sanousi, (2013):** Molecular characterization of infectious bronchitis viruses isolated from broiler and layer chicken farms in Egypt during 2012. *International Journal of Veterinary Science and Medicine*, 1: 102-108

**Stachowiak,B.; Key,D. W.;HuntonP.;GillinghamS. And Nagy,E´. (2005):** Infectious bronchitis virus surveillance in Ontariocommercial layer flocks, *Journal of Applied Poultry Research*, vol. 14, no. 1, pp. 141–146.

**Starciuc,N., Natalia Osadci, T. Spataru and Rita Golban(2012):**The Histological Changes in Lungs on Chickens Vaccinated against Avian Infectious Bronchitis with Strains Ma5+Clon30 and H-120Bulletin USAMV serie. *Veterinary Medicine*, 69(1-2)

**Sultan, H.A., Tantawi, L., Youseif, A.I. and Ahmed, A.A.S. (2004):**Urolithiathis in whitecommercial egg laying chickens associated with an infectious bronchitis virus. 6th SciConfEgypt Vet PoultAssoc 155-169.

**Suvarna,k.s Layton,ch and banchroft (2013):**Theory and practis of histological techniques.4th ed,newyork.churchill,Livingston.

**Tawfik ,H.H. ,Salama, E.,Hassan,M.O. and Ahmed,A.(2013):**Preparation and evaluation of live bivalent infectious bronchitis vaccine in chicken. *Researcher*. 5(3):31-35.

**Terregino C, Toffan A, Serena Beato M, et al.(2008):**Pathogenicity of a QX strain of infectious bronchitis virus in specific pathogen free and commercial broiler chickens, and evaluation of protection induced by a vaccination programme based on the Ma5 and 4/91 serotypes. *Avian Pathol*. 37:487–493.

**Wijimenga, W. (2009):** Survey of infectious bronchitis in Western Europe. *Int Poultry Prod*. 17:23.

**Yu L, Jiang Y, Low S, Wang Z, Nam SJ, Liu W, Kwang J (2001):** Characterization of three infectious bronchitis virus isolates from China associated with proventriculus in vaccinated chickens. *Avian Dis*, 45:416-424.

**Ziegler, A.F., Ladman, B.S., Dunn, P.A., Schneider, A., Davison, S., Miller, P.G., Lu, H., Weinstock, D., Salem, M., Eckroade, R.J. & Gelb, J. Jr. (2002).** Nephropathogenic infectious bronchitis in Pennsylvania chickens 1997-2000. *Avian Disease*. 46, 847-858.